

## Neurological and neuropsychological complications in the course of chronic Whipple's disease – case report

Izabela Dymon<sup>1</sup>, Justyna Tabaka-Pradela<sup>1</sup>, Katarzyna Knast<sup>1</sup>,  
Dominika Dudek<sup>2</sup>, Monika Rudzińska<sup>1</sup>

<sup>1</sup> Chair and Department of Neurology, School of Medicine, Medical University of Silesia

<sup>2</sup> Department of Affective Disorders, Chair of Psychiatry, Faculty of Medicine,  
Jagiellonian University Medical College

### Summary

**Introduction.** Whipple's disease (WD) is a chronic, multisystemic infectious disease caused by Gram-positive bacillus *Tropheryma whipplei* (*T.w.*). Its common symptoms arise in the digestive system, however, during the infection the CNS (Central Nervous System) may also be affected.

**Aim.** The aim of this work is to present a case report of a patient diagnosed with Whipple's disease with dominant neuropsychological and behavioural complications in the late phase.

**Conclusions.** Whipple's disease is a rare disease with possible neurological and neuropsychiatric complications. Neurological disorders (eye movement disorders, myoclonus, oculoskeletal myorhythmia, progressive dementia) may develop in spite of correct pharmacological treatment. Apart from its classical symptoms, unspecified cognitive function disorders and autonomic nervous system disorders may develop. Providing right antibiotic treatment may not always lead to complete remission or prevent neuropsychiatric complications. However, early diagnosis and clinical alertness allow to administer right treatment and improve further prognosis.

**Key words:** Whipple's disease, neurological complications, behavioural symptoms.

### Introduction

Whipple's disease is a chronic, multisystemic, infectious disease [1–3]. Occurrence of cognitive, affective and behavioural disorders in the course of the disease results

in referring the patient, in the first place to the psychiatric diagnosis and treatment, thus delaying the correct diagnosis. The disease was first described as an intestinal lipodystrophy in 1907 by George Hoyt Whipple. He found specific morphological changes of intestinal lymph nodes and the digestive tract [1, 4–6]. *Tropheryma whipplei*, gram-positive bacillus, which looks like a tubercle bacilli and is similar to antigens of streptococcus type B and D and also *Shigella flexneri* bacilli causing dysentery, is an aetiological factor in Whipple's disease [3, 7–10].

Whipple's disease is a rare disorder, affecting about 0.01% of the population, in spite of the fact that the number of asymptomatic carriers of the bacteria (in saliva and intestines) is estimated at 3–5% [11, 12]. In 98.5% of the cases, the disease affects Caucasian male patients with the peak among 40–50 year-olds [2, 11]. Each year, 18–30 new cases of WD are registered worldwide [11, 12].

The clinical picture of WD is not typical. Especially the onset might be identical to other digestive tract diseases. Diarrhoea, with or without blood, fever, abdominal pain, lymphadenopathy and loss of weight are the most common symptoms of *Tropheryma whipplei* infection. Infections might be accompanied by skin hyperpigmentation and serositis. Migrant polyarthritis, without abdomen signs (80% of cases), might occur before other symptoms develop. It mainly affects big joints (in 20% vertebral) and it is not destructive in nature [2–4, 13–16]. In the course of the disease exacerbations and remissions are observed.

Neurological symptoms can appear in 20–40% cases during the course of WD [1–4]. Usually there are eye movement disturbances, wide-based gait, memory and concentration problems, and behaviour/personality disorders. Depression, sleep disorders, disturbances of the state of consciousness, encephalitis and meningitis, may also appear [1, 2, 4, 17–19].

The increased level of acute phase proteins, microcytic anaemia with iron deficiency, hypoalbuminemia, dyselectrolytemia (hypokalaemia, hypocalcaemia) are most often observed. In addition, numerous organ pathologies and deficiency syndromes (in most cases vitamin D and K deficiency) result from malabsorption syndrome [20], and are also related to PAS-positive macrophages located in different organs (small and large intestine, stomach, liver, pancreas, kidneys, heart, lungs, CNS, body fluids) [4, 5, 21, 22].

Whipple's disease diagnosis is based on histopathology examination of the duodenum or small intestine tissue taken during the deep endoscopic procedure or genetic examination of the tissues or body fluids [23]. During the microscopic examination characteristic images of small intestinal mucosa laden with distended foamy PAS-positive macrophages in the lamina propria and Gram-positive rod around, with dilated mucosal and submucosal lymphatic vessel and also destruction of villi can be observed [2, 4, 20, 24].

The suggested treatment for Whipple's disease is parenteral administration of antibiotic that easily penetrates the blood-brain barrier (e.g. Ceftriaxone 2 g intravenously once a day for 14 days) and afterwards 12-month oral administration of trimethoprim/sulfamethoxazole (2 x 1 pill 960 mg) [5]. The effectiveness of treatment is based on periodic microscopic (biopsy of small intestinal mucosa) examination and biochemistry

examination with an emphasis on acute phase protein and inflammation parameters and control of other deficiencies [1, 4, 5, 19, 25–28].

With proper treatment short-term prognosis is good, but relapses can occur after a few years, even in the case of proper and correct medical treatment. Literature describes 2–33% of cases of disease recurrence after an average duration of approx. 5 years. This applies especially in patients with CNS involvement, and patients treated with a single antibiotic and those treated with an antibiotic that does not penetrate blood-brain barrier. The absence of response to treatment or frequent recurrences may result in extreme cachexia, ending in death [5, 15]. Non treatment of the disease manifested by neurological symptoms may lead to a serious state and may result in death within a year.

### Case report

A 54 years old patient, with higher education, married, with 1 child (adult son), a bank employee till May 2010, professionally active till 2013, currently a pensioner, without being burdened by a family history of psychological and neurological diseases. He was admitted to the Neurological Clinic of the Central Teaching Hospital in Katowice to be diagnosed due to his general state of health deteriorating for approx. 1.5 years, gradually progressing neurological symptoms in the form of eyeball movement disorder with diplopia, high levels of fatigue and ptosis in eyelids, speech and memory disorder, excessive drowsiness with psychomotor retardation, and gait and balance disorder with frequent falls.

The patient with a history of thrombophilia in the course of congenital coagulopathy with Factor V Leiden gene mutation, Diabetes mellitus type 2, chronic obstructive pulmonary disease, past pulmonary embolism in 2006 with recurrent deep venous thrombosis in the right lower limb. Moreover, the history revealed that decreased effort tolerance, recurrent pains and swelling of the joints of upper articulations, erythematous-exfoliating spots on the surface of the skin of the thorax have been observed for the last 10 years. He has been hospitalised several times since February 2010 on Internal Wards for digestive complaints manifested by cramping abdominal pains, steatorrhea, significant weight loss (approximately 36 kg in half a year) and persistent subfebrile body temperature. Laboratory tests revealed elevated inflammatory parameters, anaemia, hyperproteinemia and dyselectrolytemia. The findings of endoscopic examination suggested non-specific inflammation of intestines. The patient was observed for Leśniowski-Crohn's disease. Diagnosis of Whipple's disease was given on the basis of a few months of empirical treatment and repeated diagnostic examinations of the large intestine (histopathological examination). Treatment with antibiotics administered parenterally was introduced and continued with oral administration of trimetoprim+sulfamethoxazole for 12 months. Improvement of general condition of the patient's health has been observed since the treatment was introduced. It correlated with better well-being of the patient, improved laboratory parameters and body mass gain. The patient's condition was stable for the following 1.5 years. The treatment of primary disease and accompanying diseases was continued. Since the beginning of

2013, gradual growth of neurological and psychiatric symptoms was observed. They included: apathy, memory disturbances, change of mood, adynamia with excessive drowsiness. Gradually deviation of cranial nerves, autonomic nervous system, walk and balance disturbances with frequent falls and posture disturbances were observed. At the same time, behavioural and neurological deficiencies without intensified symptoms of digestive tract were dominant in the clinical picture.

On neurological examination performed on admission, the following symptoms were observed: psychomotor retardation, hypomimia, frontal release signs, dysarthria, eyeball movement paralysis to the sides and upwards, tetraparesis with marked intensified muscular tone of mixed type (pyramidal-extrapyramidal), myoclonus in the face, right upper limb and wide-based gait, activity impairment and autonomic system disorders.

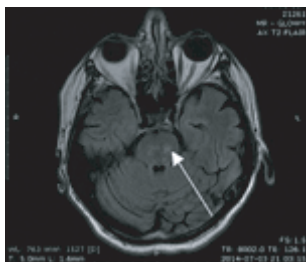
Neuropsychological examination was dominated by disturbances of cognitive functions manifested by slight dementia of fronto-subcortical character. Weakened processes of concentration, verbal and auditory learning, remembering and recognition, verbal fluency and performance functions, mood compensation, as well as decrease of drive were observed. The results of more detailed tests were as follows: MMSE: (Mini Mental State Examination; uncorrected result) 23 points; CDT (Clock-Drawing Test): performance slightly weakened (semantic errors) (-, +, +); TMT (Trial Making Test): visual deficiency – qualitative test evaluation: part A: correct, part B: difficulties with instructions; AVLT (Rey Auditory Verbal Learning Test): raising learning curve, with the features of fatigability; BDI (Beck Depression Inventory): 7 points, with no features of depression; BVRT (Benton Visual Memory Test): correct answers: 9, errors: 1.

Psychiatric examination showed that the patient was generally well-oriented, logical in verbal contact, speech was blurred, mood with tendency to indifferences. Affect was slightly vital, thinking impaired, the patient complained of memory disturbances, no features of movement anxiety were observed. Simple activity was retained; however, complex activity was weakened. Fatigability, psychomotor retardation and apathy were noticed. No hallucinations or delusions were observed, the patient contraindicated suicidal thoughts and tendencies. The patient complained of sleep disturbances with immoderate drowsiness during the day.

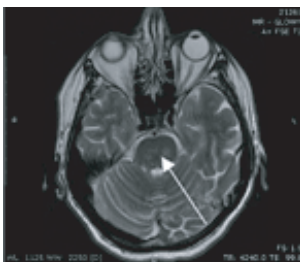
MRI of the head (Figure 1 and 2) showed several minor hyperintense foci located subcortically in T2 images (mainly in the region of bridge and mesencephalon and single periventricular white matter lesions (Figure 3).

## Discussion

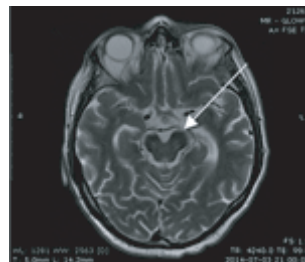
It must be stressed that the symptoms of CNS involvement in this disease, include neurological symptoms that become visible relatively late, usually, when significant neurological deficiencies are present. In our case the first symptoms suggesting the possibility of CNS involvement were behavioural disorders and dementia (memory failures, mood disorders, sleep disorders, apathy). It was only after this that typical neurological symptoms appeared suggesting the possibility of CNS processing disorder, in the absence of clinical manifestation in the gastrointestinal tract during this period.



**Figure 1. MRI of the head with contrast in T2-weighted images and T2 FLAIR images**



**Figure 2. MRI of the head with contrast in T2-weighted images and T2 FLAIR images**



**Figure 3. MRI of the head with contrast in T2-weighted images and T2 FLAIR images**

On the other hand, behavioural disturbances might have resulted from a long lasting course of disease, relatively late diagnosis, multitude of symptoms, several hospitalisations which results in the lack of socio-occupational stabilisation of the patient. It should also be noted that the patient was in the phase of gastroenterological remission when neurological and neuropsychological symptoms were disclosed. Similarly unusual is the fact that neurological and neuropsychiatric symptoms appeared when antibiotic therapy was used at length. Among the previously described cases, antibiotics resulted in remission of neurological symptoms (sight disorder, focal symptoms) as well as withdrawal of symptoms of dementia and behavioural disorders. Resistance to this treatment resulted in fast progression in the course of the disease, as opposed to gradual progression of the disease in the observed patient.

Whipple's disease with its hidden, chronic and multiorgan clinical picture is usually characterised by three stages of development. The first to appear are nonspecific disturbances in the work of joints in the upper and lower limbs which – as literature shows – precede other symptoms of the disease 6 years ahead in  $\frac{3}{4}$  of cases [16]. They correlate with the changes in physical examination and laboratory tests which are seronegative. Moreover, the patients complain of general malaise, fatigue, weakness, digestive tract disturbances, cough and pains in the thorax, subfebrile body temperature [2, 4, 22, 29]. The second stage of the disease is manifested by gastroenterological disturbances such as fatty diarrhoea with crampy abdominal pains and marked body weight loss. The following stage results in cachexia, malabsorption syndrome, hyperpigmentation of skin and lymphadenopathy [4, 14–16]. In the presented patient, the diagnosis and starting the appropriate treatment took nearly 5 years, and almost 15 years had passed since the beginning of arthralgia to the diagnosis.

The age of the patient, nonspecific, multitude, migrating, polyarticular arthritis with deteriorating decrease in effort tolerance, through typical manifestation of complaints in digestive system and secondary to the symptoms: cachexia, malabsorption syndrome with accompanying skin lesions and neurological complications, support non-pathognomic but highly probable picture of intestinal lipodystrophy [5, 30–32]. The diagnosis of Whipple's disease is based on the histopathological examination of

the small intestine and disclosure of macrophages stained with PAS method [2, 3, 5, 22]. PAS-positive macrophages may also be shown in the course of other diseases. Therefore, it is recommended to carry out simultaneous macroscopic examinations and the analysis of genetic material of *Tropheryma whippelii* (T.w.) using polymerase chain reaction (PCR) method [23, 24, 33]. If, however, the sample of intestine does not show PAS-positive reaction, samples of tissues from other organs (liver, kidneys, stomach, cerebrospinal fluid, lymph node fluid and fluid from the hyaline body ad even brain may be taken to give right diagnosis. In case of negative outcomes of all examinations, and high probability of Whipple's disease, stereotactic brain biopsy is recommended [19, 34]. Examination of cerebrospinal fluid (CSF) does not show specific changes in about half of the cases. In order to monitor the therapy during its course, it is recommended to repeat the CSF test after 2 weeks, 6 months and 3 years of treatment, even if the first test is characterised by a relatively low concentration of protein and non-specific pleocytosis [19, 34]. In the differential diagnosis of intestinal lipodystrophy the following diseases are taken into consideration: neurodegenerative diseases (primarily progressive supranuclear palsy – PSP, Alzheimer's disease – AD, dementia with Lewy bodies), infectious diseases and complications involving CNS (syphilis, neuroborreliosis, neurobrucellosis, tuberculosis, bacterial, parasitic and viral infections), prion diseases (Creutzfeldt-Jakob disease – CJD), malabsorption syndrome, neurological complications of metabolic disorders, cancer and paraneoplastic syndromes, and autoimmune diseases (sarcoidosis, vasculitis) [17, 24].

Neuropsychological tests and clinical neurological examinations, including neuroimaging of the brain, without confirmation of histopathological or genetic infection are not able to unambiguously confirm the diagnosis of the Whipple's disease [5]. However, for proper evaluation, it is important whether the behavioural and depressive disorders lie in the clinical picture of the disease and are the result of damage to CNS, or they are the patient's response to the prolonged process of the disease or coexisting multi-organ complications, or the result of the ongoing process of dementia [1, 2, 4, 35]. Cognitive deficits, impaired cortical and higher brain function (memory, attention, executive function, praxis) and progression of personality and behaviour disorders develop without being noticed. They are often identified as symptoms of getting old, developing or co-existing Alzheimer's disease. It should be highlighted that in patients with Whipple's disease, demonstrating the symptoms in regular specific psychological tests, and possible progression observed in subsequent studies, may be the evidence of the ineffectiveness of pharmacotherapy and/or progression of the disease, which significantly worsens the prognosis [2, 17]. In psychopharmacotherapy for symptomatic intestinal lipodystrophy, medicines are used in all groups, depending on the type and severity of psychiatric disorders. Among others: mood stabilizers, neuroleptics (antipsychotics and anxiolytics) hypnotics and tranquilizers, as well as psychoanaleptics (antidepressants, psychostimulants, nootropics, and pro-cognitive drugs) are used. There are no specific contraindications relating to the use of the above mentioned groups of medicines, except general contraindications and those related to the clinical condition of the patient, as well as resulting from accompanying diseases. Prolonged intake of psychotropic medication requires regular monitoring of biochemical and morphotic parameters of blood and urine.



## Conclusions

Neuropsychological and behavioural symptoms can occur in the course of Whipple's disease. They may be primarily related to intestinal lipodystrophy or constitute secondary symptoms in the treatment of multiorgan complications of this disease. Slow progression of dementia, supranuclear palsy, headaches, myoclonus, hypothalamus dysfunction and oculo-skeletal myorhythmia are the most common manifestations of Central Nervous System symptoms in the course of Whipple's disease [1, 2, 5, 18, 19, 29]. Even right antibiotic therapy cannot provide full remission of disease and subsidence of complications related to Peripheral Nervous System. The case confirms that multi-specialist clinical care allows for detection of neurobehavioural disturbances in the early stage of involvement of the Central Nervous System [3, 5, 36]. Non-specific course and clinical picture of intestinal lipodystrophy are still a great diagnostic challenge for clinicians [5].

## References

1. Compain C, Sacre K, Puéchal X, Klein I, Vital-Durand D, Houeto JL. et al. *Central nervous system involvement in Whipple disease: clinical study of 18 patients and long-term follow-up*. *Medicine (Baltimore)* 2013; 92(6): 324–330.
2. França MC Jr, de Castro R, Balthazar MLF, Malveira GLS, Pirani C Jr, Deus-Silva LA. et al. *Whipple's disease with neurological manifestations case report*. *Arq. Neuropsiquiatr.* 2004; 62(2-A): 342–346.
3. Matthews BR, Jones LK, Saad DA, Aksamit AJ, Josephs KA. *Cerebellar ataxia and central nervous system Whipple disease*. *Arch. Neurol.* 2005; 62(4): 618–620.
4. Kiyooki U, Takashi S, Tomonori Y, Takahito M, Yoshie I, Hiroji S. et al. *Central nervous system relapse of Whipple's disease*. *Intern. Med.* 2012; 51(15): 2045–2050.
5. Wroe SJ, Pires M, Harding B, Youl BD, Shorvon S. *Whipple's disease confined to the CNS presenting with multiple intracerebral mass lesions*. *J. Neurol. Neurosurg. Psychiatry* 1991; 54(11): 989–992.
6. Whipple GH. *A hitherto undescribed disease characterized anatomically by deposits of fat and fatty acids in the intestinal and mesenteric lymphatic tissues*. *Johns Hopkins Hosp. Bull.* 1907; 198: 383–389.
7. Cohen AS, Schimmel EM, Holt PR, Isselbacher KJ. *Ultrastructural abnormalities in Whipple's disease*. *Proc. Soc. Exp. Biol. Med.* 1960; 105: 411–414.
8. Cheers WC Jr, Ashworth CT. *Electron microscopic study of the intestinal mucosa in Whipple's disease. Demonstration of encapsulated bacillary bodies in the lesion*. *Gastroenterology* 1961; 41: 129–138.
9. Yardley JH, Hendrix TR. *Combined electron and light microscopy in Whipple's disease – demonstration of "bacillary bodies" in the intestine*. *Johns Hopkins Hosp. Bull.* 1961; 109: 80–98.
10. Relman DA, Schmidt TM, MacDermott RP, Falkow S. *Identification of the uncultured bacillus of Whipple's disease*. *N. Engl. J. Med.* 1992; 327: 293–301.
11. Dobbins WO 3<sup>rd</sup>. *Whipple's disease*. Springfield, III, Illinois: Charles C. Thomas, 1987.

12. Enzinger FM, Helwig EB. *Whipple's disease: a review of the literature and report of fifteen patients*. Virch. Arch. Pathol. Anat. 1963; 336: 238–269.
13. Fleming JL, Wiesner RH, Shorter RG. *Whipple's disease: clinical, biochemical and histopathologic features and assessment of treatment in 29 patients*. Mayo Clin. Proc. 1988; 63: 539–551.
14. Maizel H, Ruffin JM, Dobbins WO. *Whipple's disease: a review of 19 patients from one hospital and a review of the literature since 1950*. Medicine (Baltimore) 1970; 49: 175–205.
15. Durand DV, Lecomte C, Cathébras P, Rousset H, Godeau P. *Whipple disease. Clinical review of 52 cases. The SNFMI Research Group on Whipple Disease. Societe Nationale Francaise de Medecine Interne*. Medicine (Baltimore) 1997; 76: 170–184.
16. Puechal X. *Whipple's disease and arthritis*. Curr. Opin. Rheumatol. 2001; 13: 74–79.
17. Anderson M. *Neurology of Whipple's disease*. J. Neurol. Neurosurg. Psychiatry 2000; 68: 2–5.
18. Manzel K, Tranel D, Cooper G. *Cognitive and behavioral abnormalities in case of central nervous system Whipple's disease*. Arch. Neurol. 2000; 57: 399–403.
19. Rowland LP, Pedley TA. *Neurologia Merritta*. Vol 1. 3<sup>rd</sup> edition. Wroclaw: Urban & Partner Publishing House; 2012.
20. Dobbins WO 3<sup>rd</sup>. *The diagnosis of Whipple's disease*. N. Engl. J. Med. 1995; 332: 390–392.
21. Hendrix JP, Black-Schaffer RW, Withers P, Handler P. *Whipple's intestinal lipodystrophy. Report of four cases and discussion of possible pathogenic factors*. Arch. Intern. Med. (Chic.) 1950; 85: 91–131.
22. Ratnaike R. *Whipple's disease*. Postgrad. Med. J. 2000; 76(902): 760–766.
23. Maiwald M, Schuhmacher F, Ditton HJ, von Herbay A. *Environmental occurrence of the Whipple's disease bacterium (Tropheryma whippelii)*. Appl. Environ. Microbiol. 1998; 64: 760–762.
24. Lewicki J. *Badania histologiczne, histochemiczne i mikroskopowo-elektronowe w przypadku choroby Whipple'a*. Pol. Arch. Med. Wewn. 1973; 50: 821–825.
25. Loughran D, Beale L, Lodge F, Habboush H, Stock D. *Whipple's in the valleys: a case of Whipple's with thrombocytopenia and endocarditis*. J. Clin. Pathol. 2014; 67(5): 445–448.
26. Feurle GE, Junga NS, Marth T. *Efficacy of ceftriaxone or meropenem as initial therapies in Whipple's disease*. Gastroenterology 2010; 138(2): 478–486.
27. Moos V, Lodenkemper C, Schneider T. *Tropheryma whippelii infection. Colonization, self-limiting infection and Whipple's disease*. Pathologie 2011; 32(5): 362–370.
28. Touitou V, Fenollar F, Cassoux N, Merle-Beral H, LeHoang P, Amoura Z. et al. *Ocular Whipple's disease: therapeutic strategy and long-term follow-up*. Ophthalmology 2012; 119(7): 1465–1469.
29. Abreu P, Azevedo E, Lobo L, Moura CS, Pontes C. *Whipple disease and central nervous system*. Acta Med. Port. 2005; 18(3): 199–208.
30. Jirout CF, Ballina GF, Fernandez SJ, Queiro SR, Ordas CC, Rodriguez PA. *Atypical manifestations of Whipple's disease*. An. Med. Interna 2001; 18: 24–26.
31. Gruner U, Goesch P, Donner A, Peters U. *Morbus Whipple's and non-Hodgkin lymphoma*. Z. Gastroenterol. 2000; 39: 305–309.
32. Lagier JC, Fenollar F, Raoult D. *Whipple's disease and Tropheryma whippelii infections in internal medicine. When thinking about it? How to treat?* Rev. Med. Interne 2014; 35(12): 801–807.
33. Hendrix JPB, Black-Schaffer RW, Withers P, Handler P. *Whipple's intestinal lipodystrophy. Report of four cases and discussion of possible pathogenic factors*. Arch. Intern. Med. 1950; 85: 91–131.
34. Gerard A, Sarrot-Reynauld F, Liozon E, Cathébras P, Besson G, Robin C. *Neurologic presentation of Whipple disease: report of 12 cases and review of the literature*. Medicine (Baltimore) 2002; 81(6): 443–457.



- 
35. Balasa M, Gelpi E, Rey MJ, Vila J, Ramió-Torrentà L, Quiles Granado AM. *Clinical and neuropathological variability in clinically isolated central nervous system Whipple's disease*. Brain Pathol. 2014; 24(3): 230–238.
  36. Black DF, Aksamit AJ, Morris JM. *MR imaging of central nervous system Whipple disease: A 15-year review*. AJNR Am. J. Neuroradiol. 2010; 31: 1493–1497.

Address: Monika Rudzińska  
Chair and Department of Neurology  
School of Medicine, Medical University of Silesia  
Independent Public Central Teaching Hospital  
40-752 Katowice, Medyków Street 14